

Mitraliskirurgi

SFKF HÖSTMÖTE 2024-10-04

FARKAS VÁNKY

THORAX- KÄRLKLINIKEN I LINKÖPING

ÖVERLÄKARE, BITR. PROFESSOR

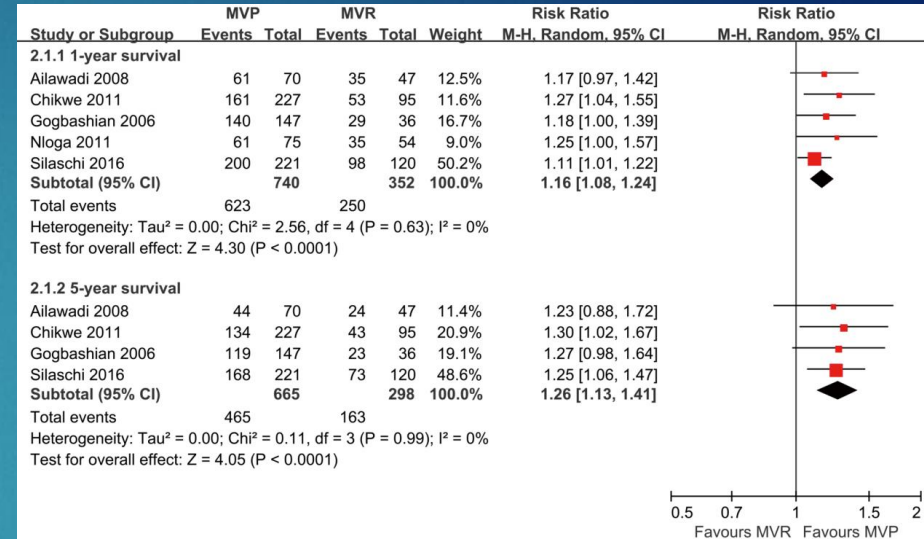
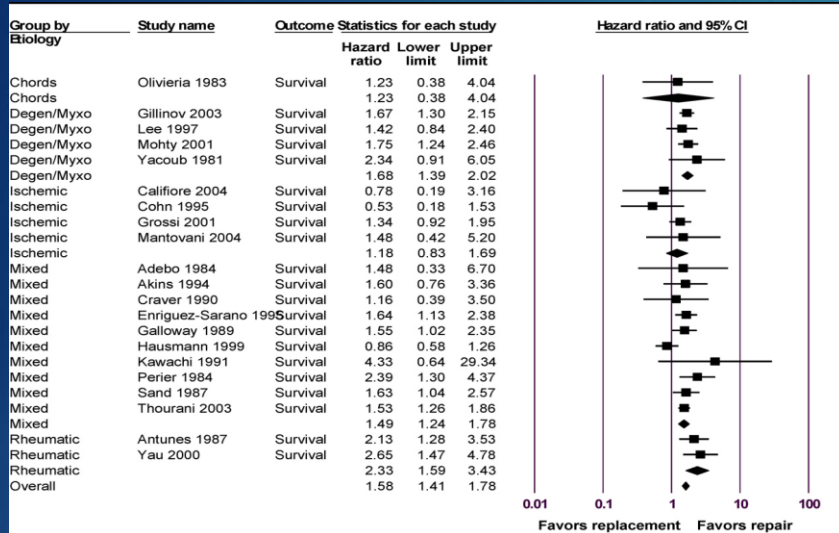
Mitraliskirurgi:

- **MVR (mitral valve replacement) – Biologisk eller mekanisk**
 - Mitralisstenos
 - Mitralisinuficiens som man inte kan laga
- **Mitralisplastik**
 - Bäst kort- och långtidsresultat oavsett ålder
 - Förutsätter att plastiken är hållbar
 - Olika tekniker används och kombineras

Repair v Replacement metaanalyser

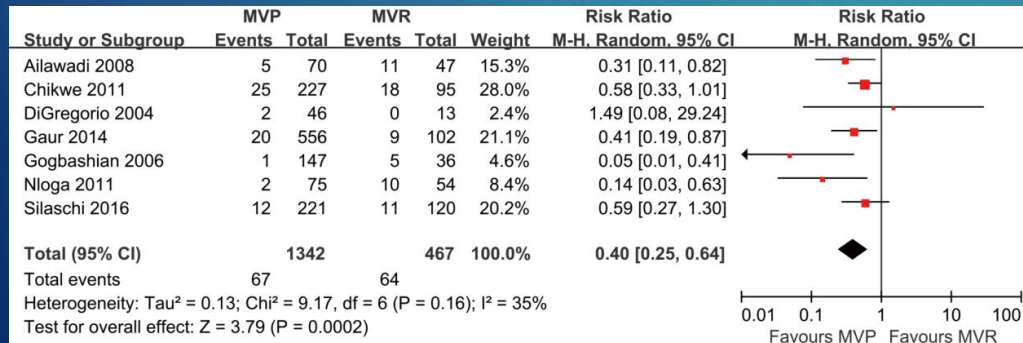
30d överlevnad

1 och 5 årsöverlevnad



J. Shuhaiber, R.J. Anderson / European Journal of Cardio-thoracic Surgery 31 (2007)

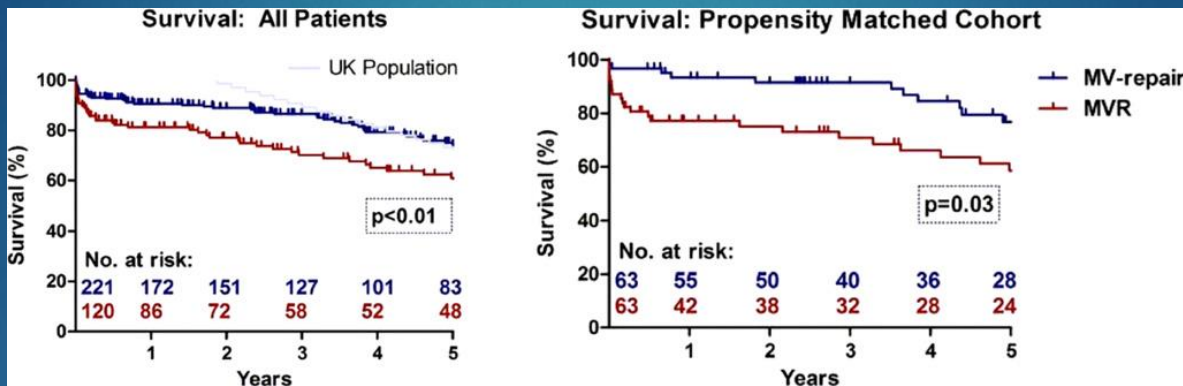
Xiaoke Shang, Rong Lu, Mei Liu, Shuna Xiao, Nianguo Dong. Journal of Thoracic Disease 2017



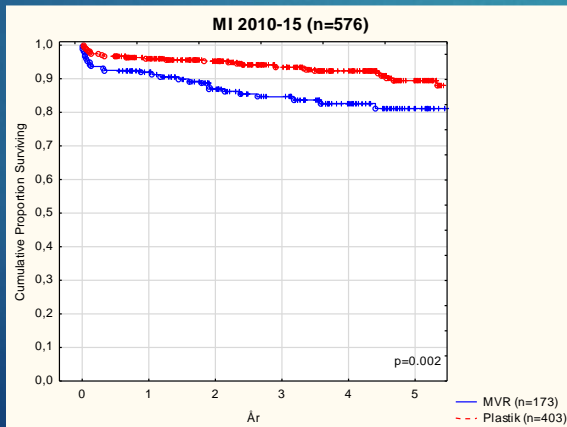
Repair v Replacement

► Patients > 75yrs, survival

Conclusions—Excellent outcomes can be achieved after MV surgery in elderly patients. Long-term survival is superior after MV-repair and the re-operation rate is low. MV-repair should be the preferred surgical approach in elderly patients. (J Am Heart Assoc. 2016)

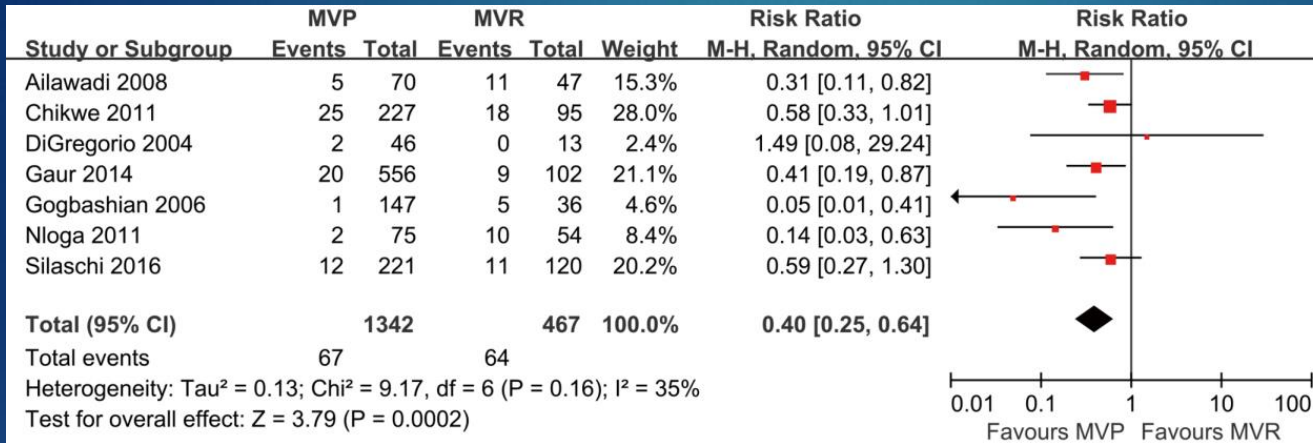


► Linköping, alla åldrar, överlevnad

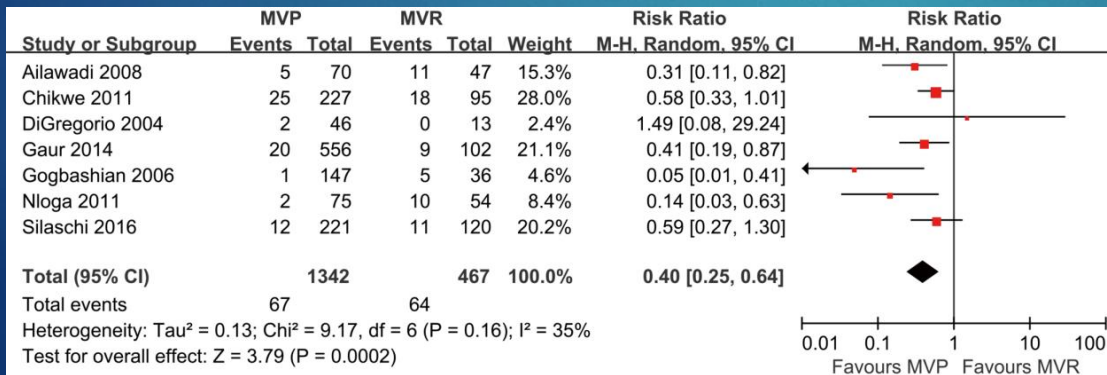


Repair v Replacement (metaanalyser)

Reoperation under uppföljningen



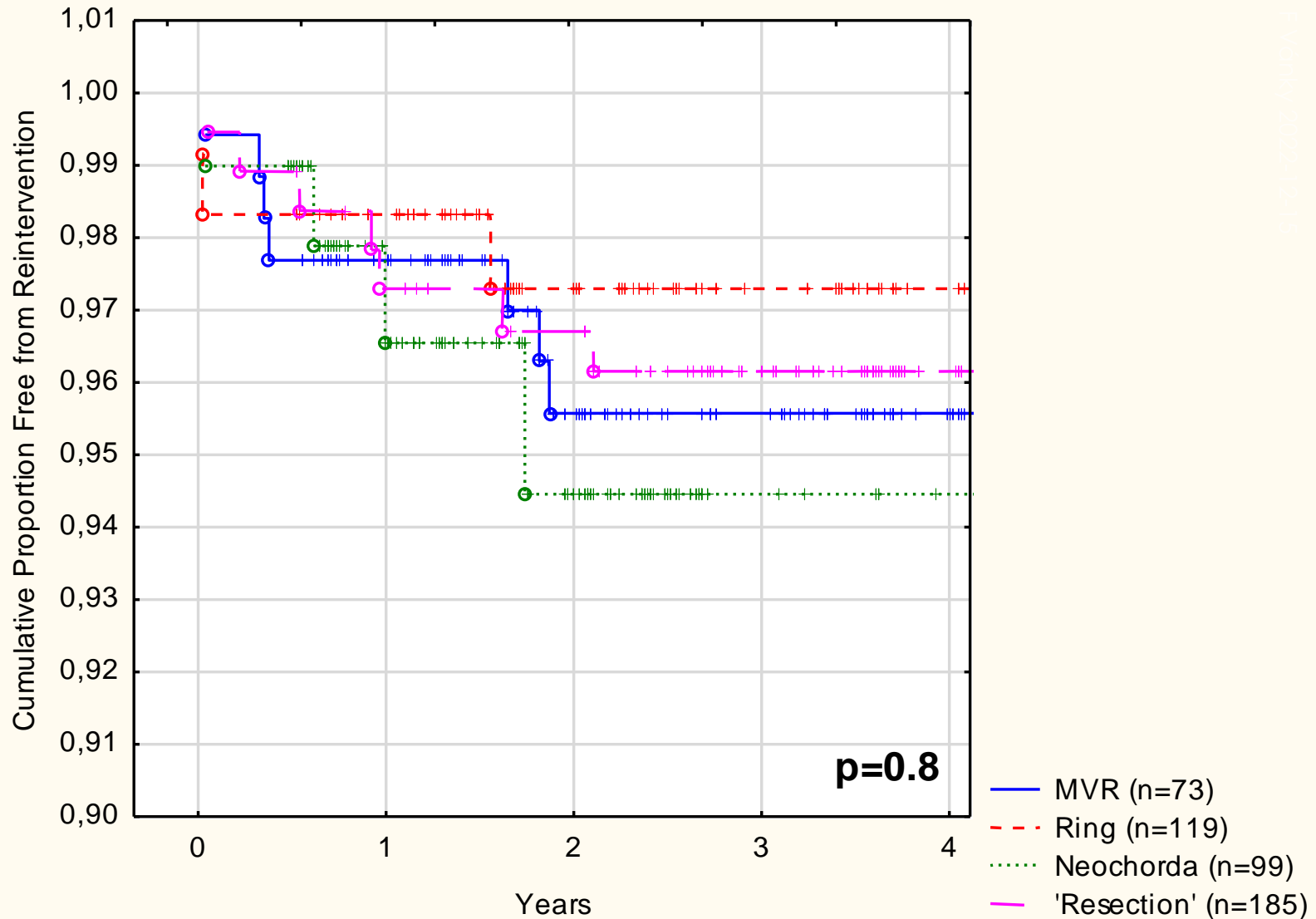
J. Shuhaiber, R.J. Anderson / European Journal of Cardio-thoracic Surgery 31 (2007)



Xiaoke Shang, Rong Lu, Mei Liu, Shuna Xiao, Nianguo Dong. Journal of Thoracic Disease 2017

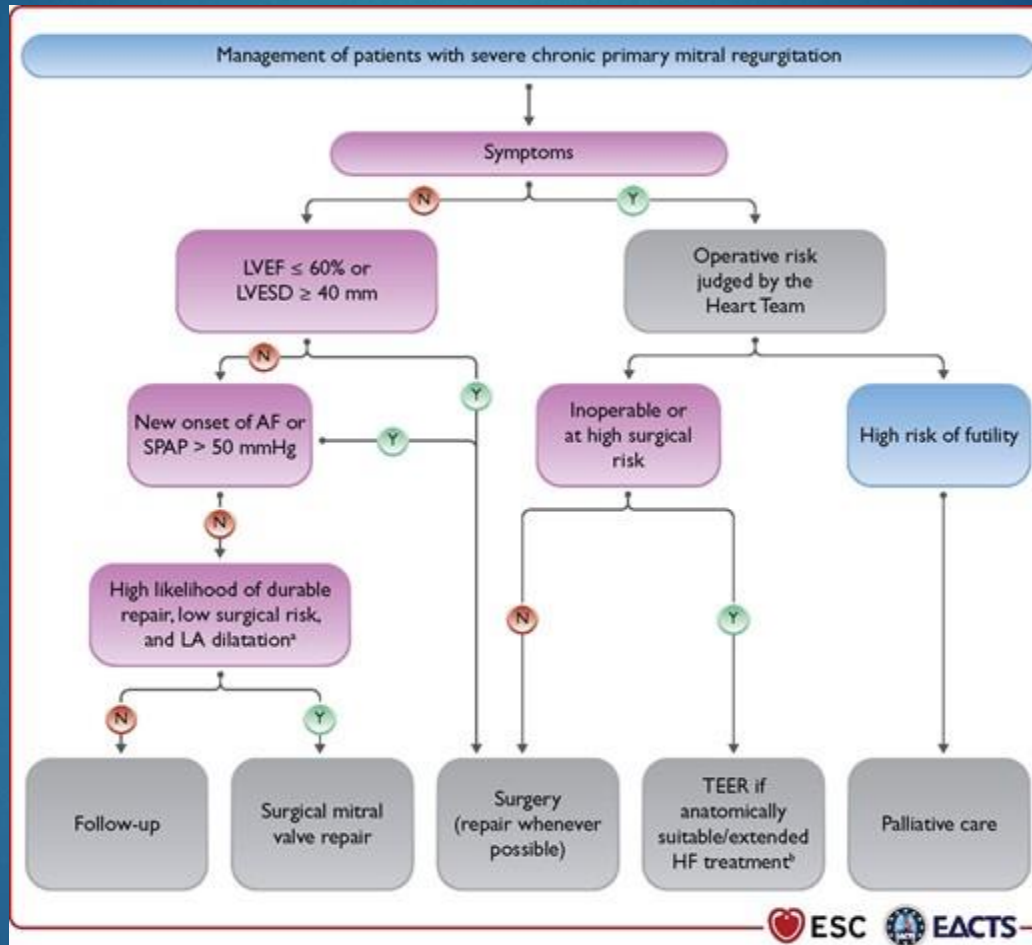
Reoperation

Reinterventionfree time MI patients



När indikationen för kirurgi är fastställd, primär MR

2021 ESC/EACTS Guidelines for the management of valvular heart disease:



Recommendations	Class ^a	Level ^b
<u>Mitral valve repair is the recommended surgical technique when the results are expected to be durable.</u> ^{293–296}	I	B
Surgery is recommended in <u>symptomatic</u> patients who are operable and not high risk. ^{293–296}	I	B
Surgery is recommended in <u>asymptomatic</u> patients with <u>LV dysfunction</u> (LVESD ≥ 40 mm and/or LVEF $\leq 60\%$). ^{277,286,292}	I	B
<u>Surgery should be considered in asymptomatic</u> patients with preserved LV function (LVESD < 40 mm and LVEF $> 60\%$) and <u>AF secondary to</u> mitral regurgitation or pulmonary hypertension ^c (SPAP at rest > 50 mmHg). ^{285,289}	IIa	B
Surgical mitral valve repair should be considered in low-risk asymptomatic patients with LVEF $> 60\%$, LVESD < 40 mm ^d and significant <u>LA dilatation</u> (volume index ≥ 60 mL/m ² or diameter ≥ 55 mm) when performed in a Heart Valve Centre and a durable repair is likely. ^{285,288}	IIa	B
<u>TEER may be considered in symptomatic</u> patients who fulfil the echocardiographic criteria of eligibility, are <u>judged inoperable or at high surgical risk</u> by the Heart Team and for whom the procedure is not considered futile. ^{299–302}	IIb	B

© ESC/EACTS 2021

Vad behöver vi veta inför kirurgi (plastik)?

Prolaps – var? hur stor?

Restriktivitet? (tenting: 0-5, 5-10, >10mm)

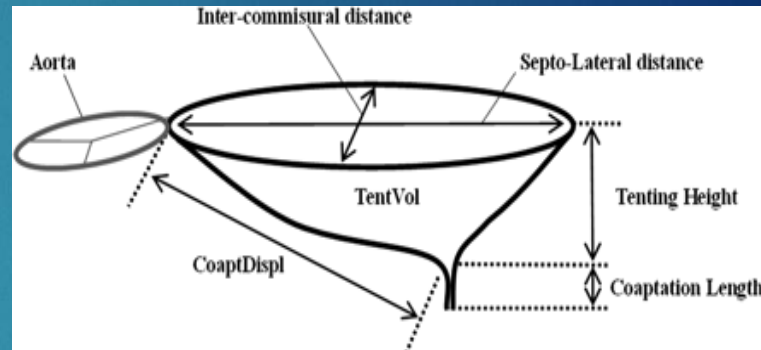
Ringmått – AP/IC

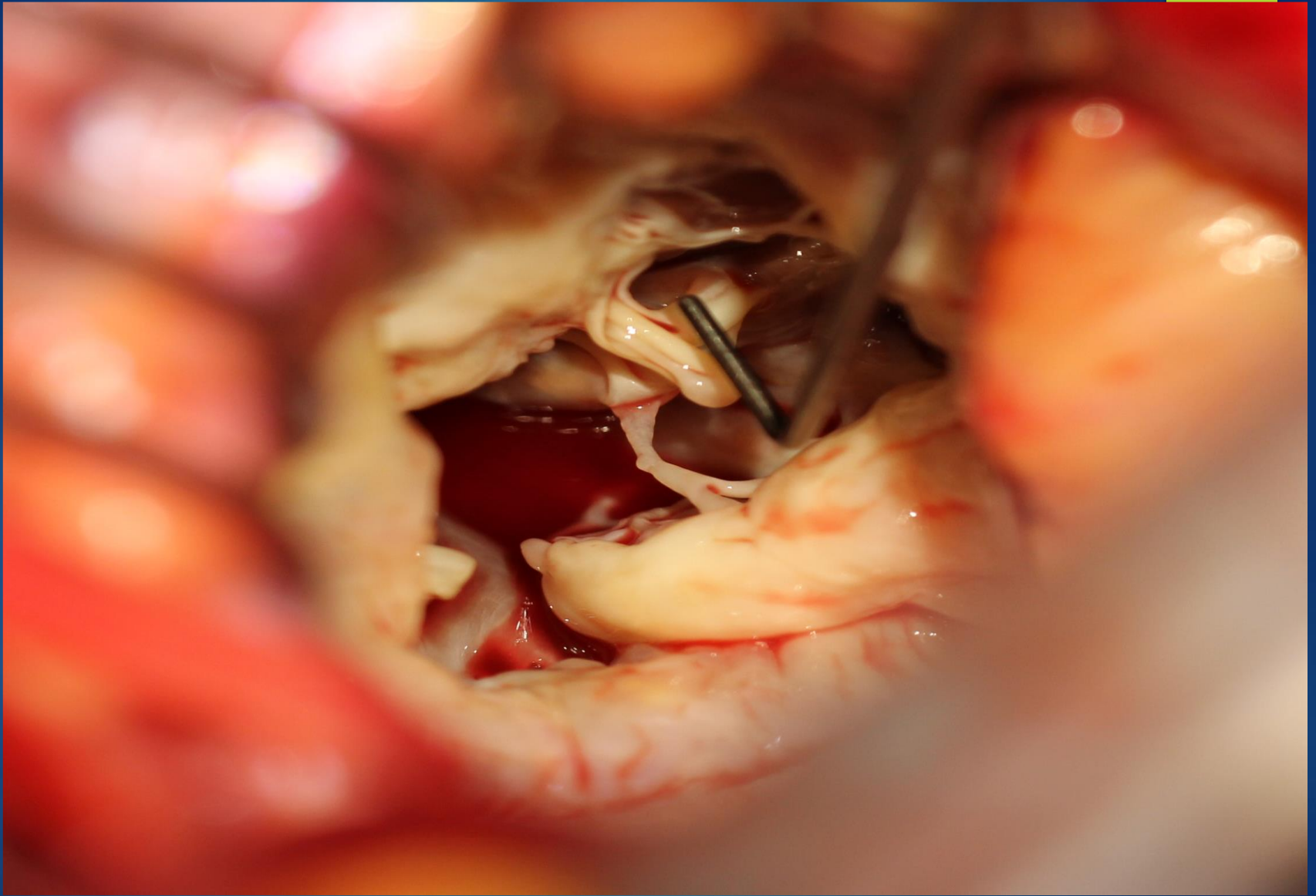
Barlow

LVOT obstruktion – tendens till SAM

Aorto-mitral vinkel

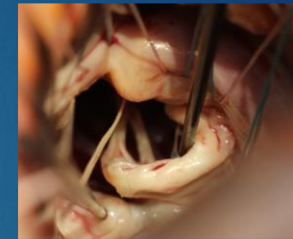
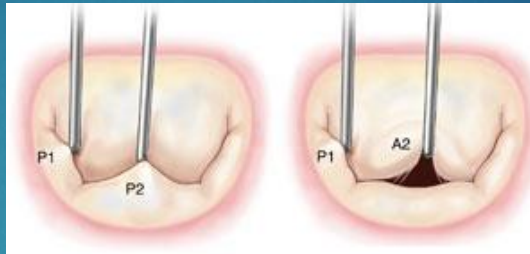Övriga vitier, koronarkärl (stenoser, anatomi), lungfunktion



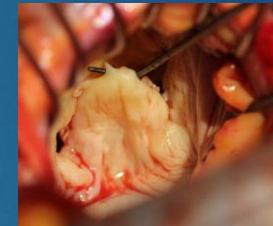
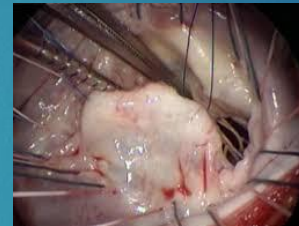

Peroperativ kirurgisk klaffanalys

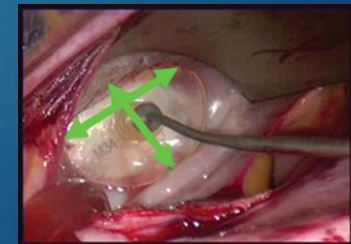
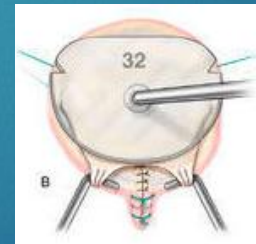
P1 referens för chorda-längd



Baksegellängd



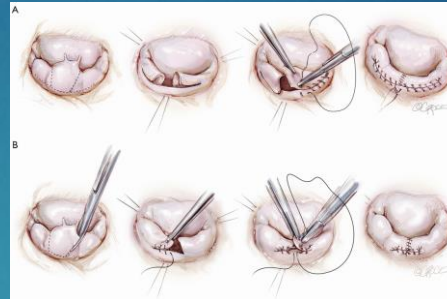Framsegelyta + IC distans -> Ringstorlek



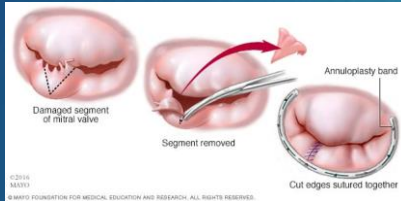
Plastikmetoder I

Resektion (endast baksegel – P2)

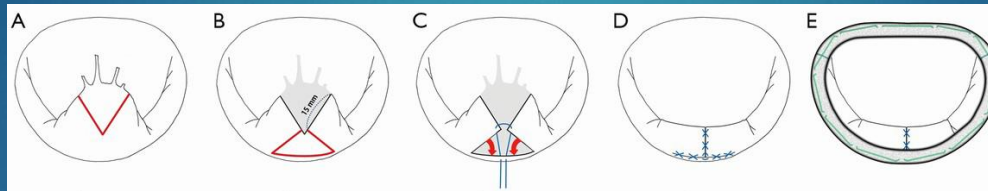
- Kvadrangulär (slidin/folding)



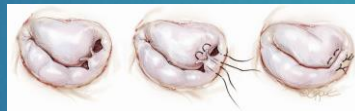- kil



- butterfly



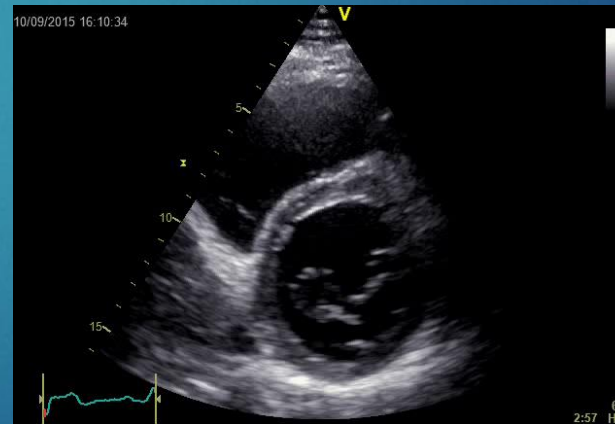
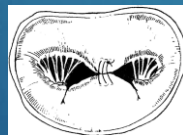
Komissurplastik



Edge-to-edge, Alfieri stich

Barlow

SAM

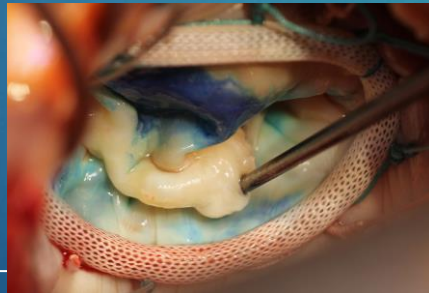
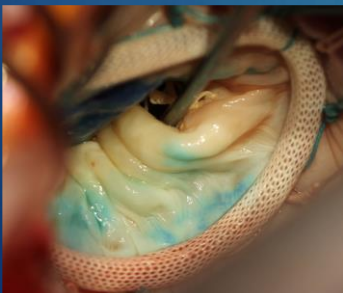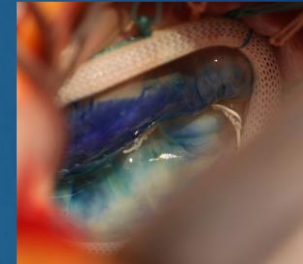
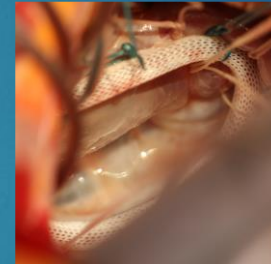
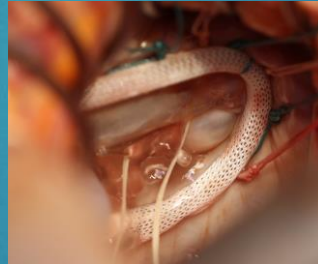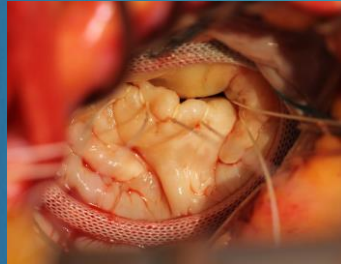
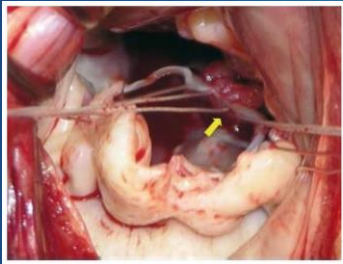
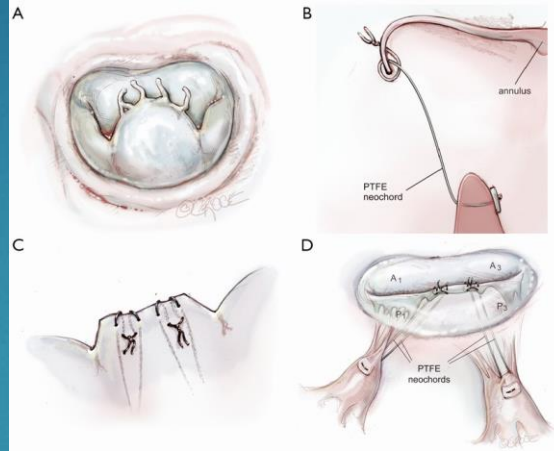


Resektionsplastik, för- och nackdelar

- Sjuk vävnad tas bort
 - Välbeprövad teknik
 - Mindre risk för SAM
-
- Endast baksegel
 - Mindre ring/ostium
 - Ingen återvändo

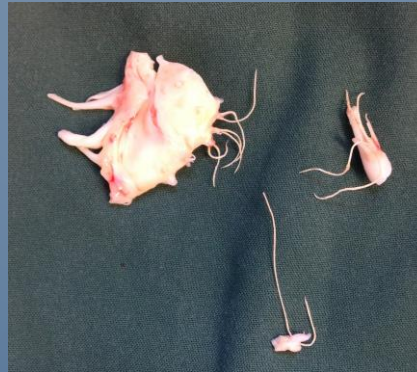Plastikmetoder II

Neochorda (Gore-Tex)

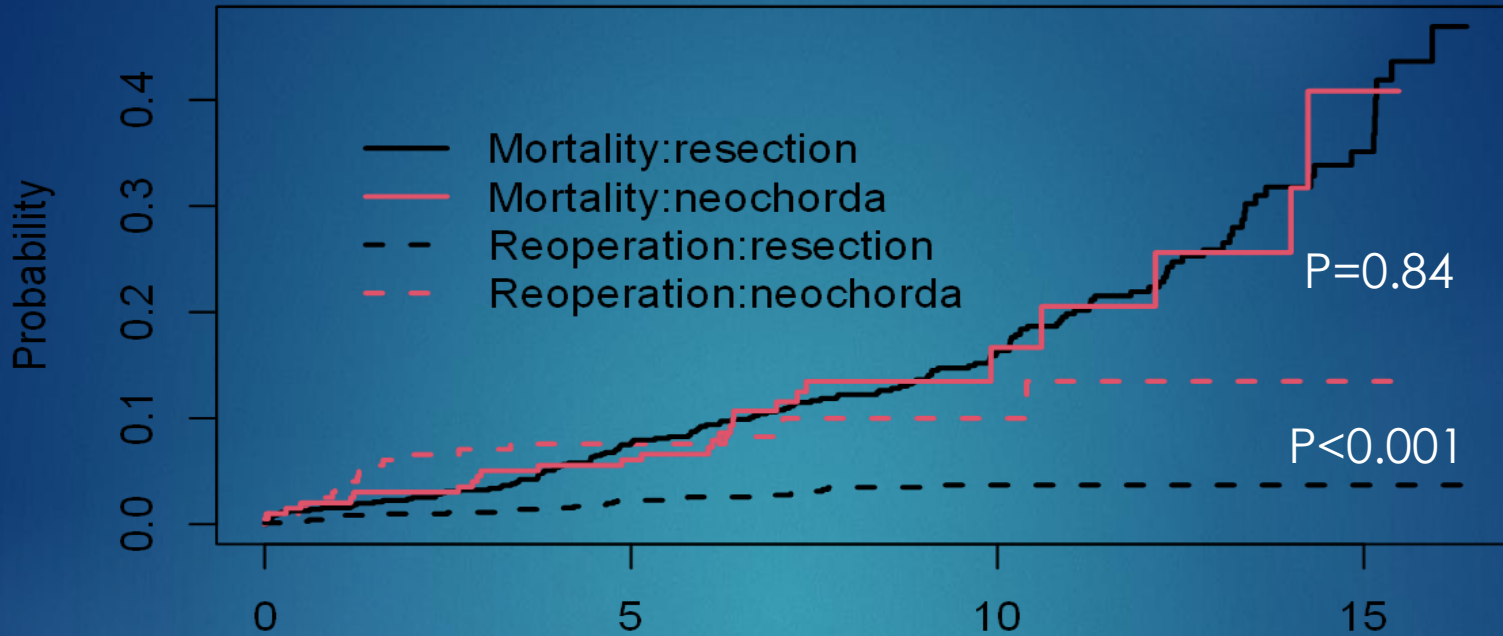


Neochorda, för- och nackdelar

- Alla klaffsegment kan åtgärdas, även omfattande Barlow
 - Kan testas och justeras
 - Större ring/ostium
-
- Sjuk vävnad kvar
 - Större risk för SAM
 - Välbeprövad (>20 år) men fortfarande vissa **frågetecken kring hållbarhet**

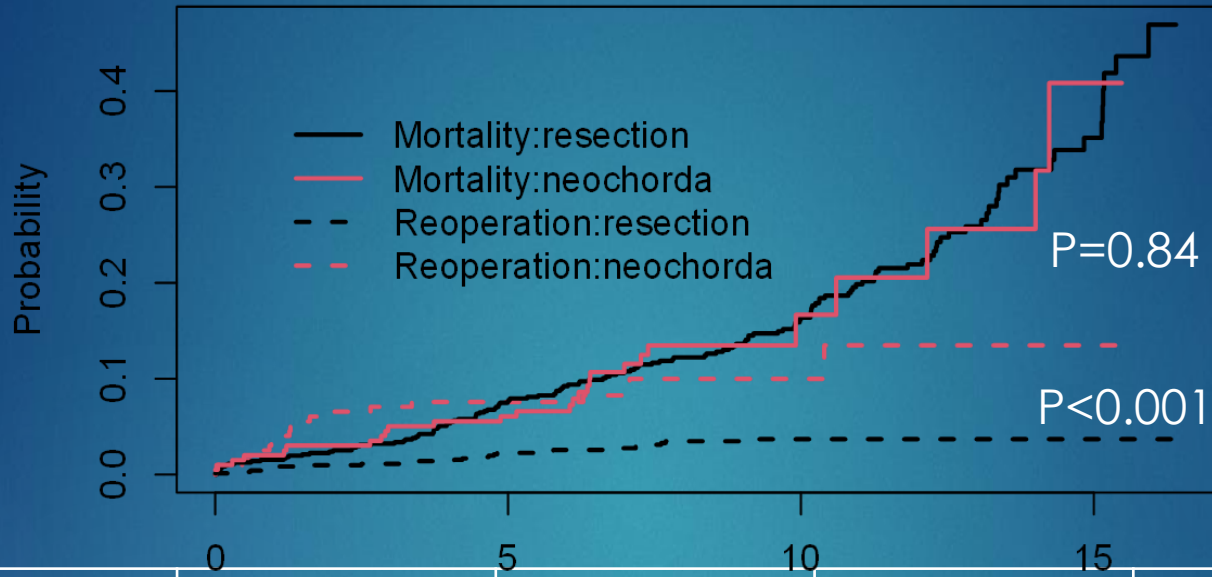


Svensk multicenterstudie (under publ)



Neochorda				
At risk	198	166	22	1
Events	0	15	18	19
Resection				
At risk	709	602	331	42
Events	0	16	24	24

Results 2

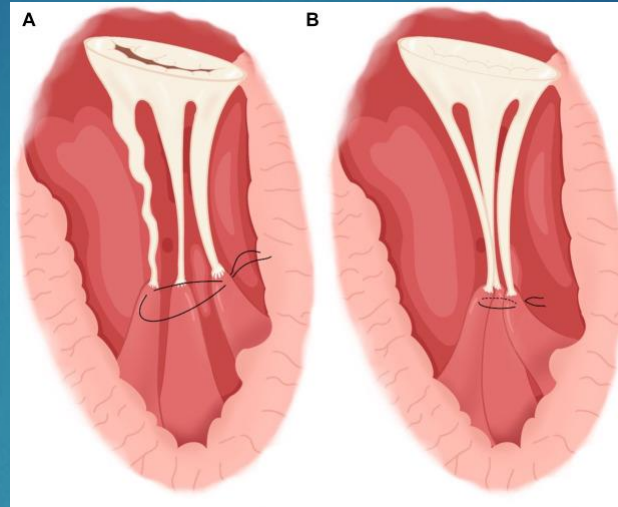


Neochorda				
At risk	198			
Events	0			
Resection				
At risk	709			
Events	0			



Plastikmetoder III

Papillarmuskelplastik



Chordaförflyttning fr PL till AL

Alltid annuloplastik med ring!

Med ytterst få undantag

Mål att eftersträva med mitralisplastiken för ett hållbart resultat:

Inget läckage


Ring - remodelering

Coaptationsyta > 3-4mm (7mm)

Coaptationsnivå nedanför annulusplanet

Coaptationsläge i anteposterior riktning

Apposition symmetrisk

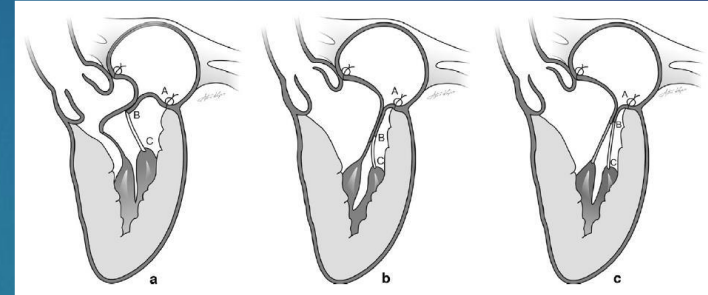


Fallgropar

Systolic anterior motion (SAM)

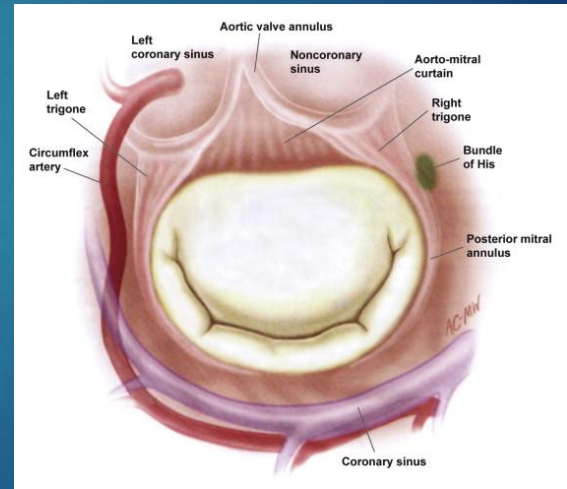
Ökad risk om:

- Baksegellängd > 2 cm (1,5 cm)
- Coapt-sept distans < 3 cm (2,5 cm)
- Hypertrof, buktande septum $> 1,5$ cm
- Vinkeln aorta- och mitralisklaffplanet $< 120^\circ$



Cx obstruktion

Aortainsufficiens

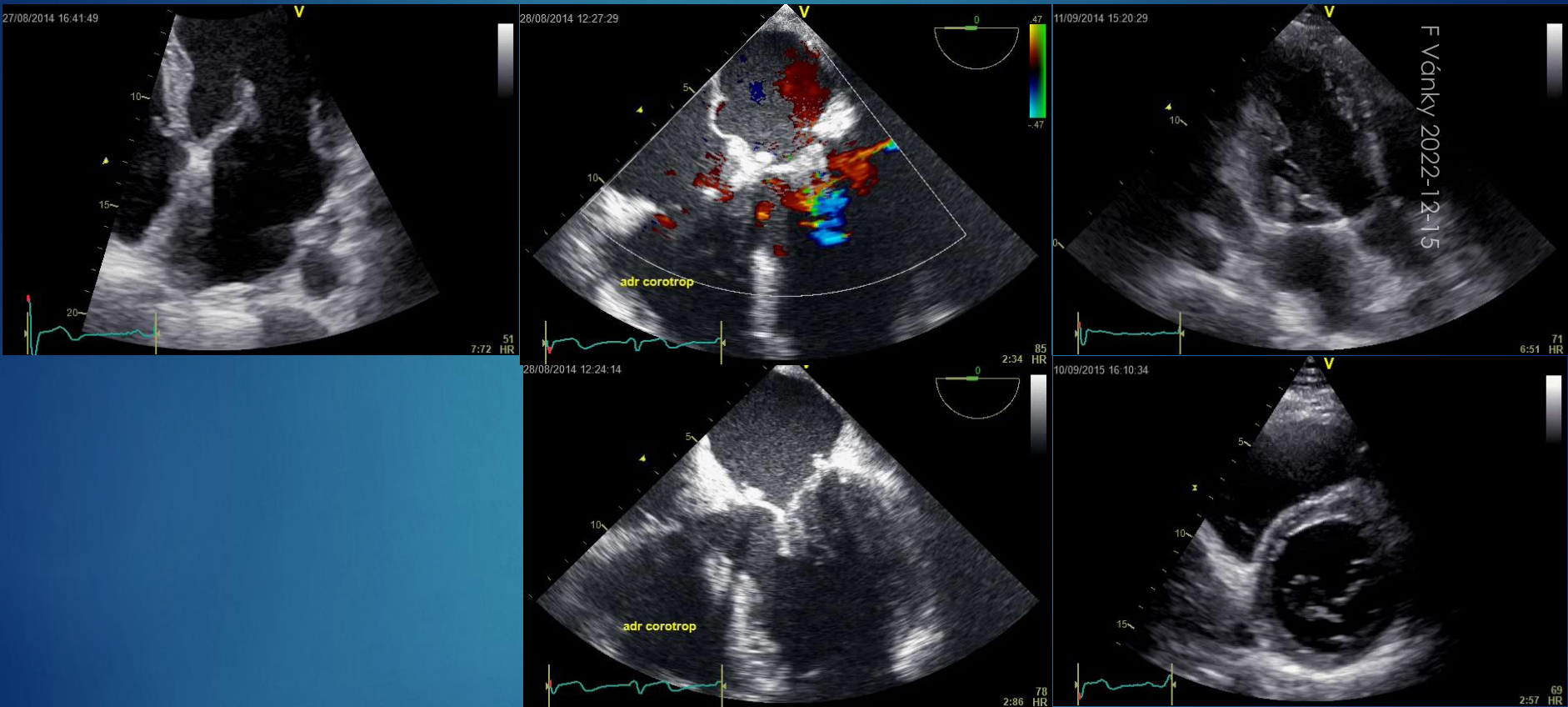


SAM (CT -57)

Preop: Barlow, dil ring, måttl MI
Mitral annulus disjunction (MAD)

Op: CE-ring
Perop: Turbulens i LVOT, SAM

Reop: Alfierisutur
Postreop: Fritt i LVOT, dubbel orifice

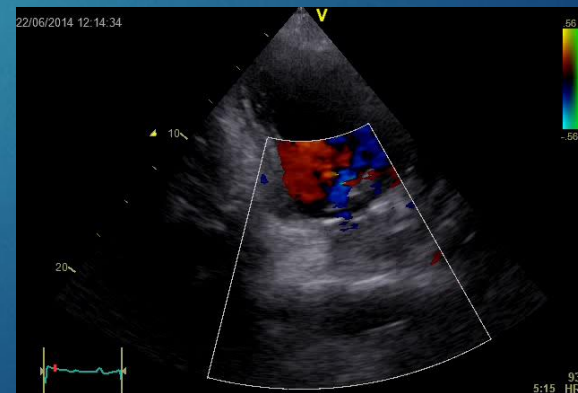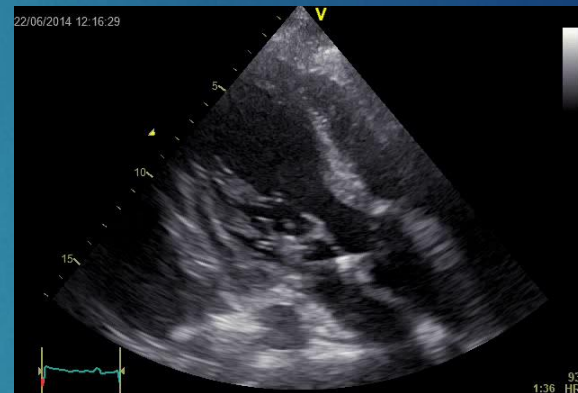
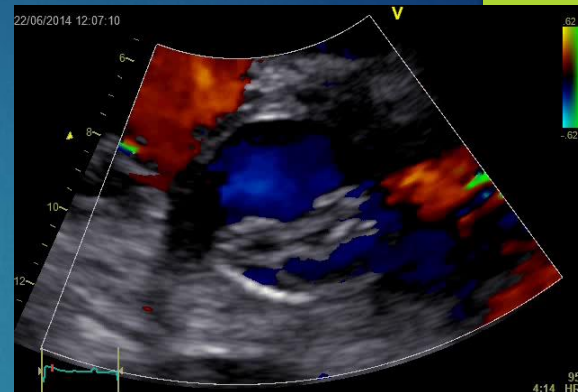
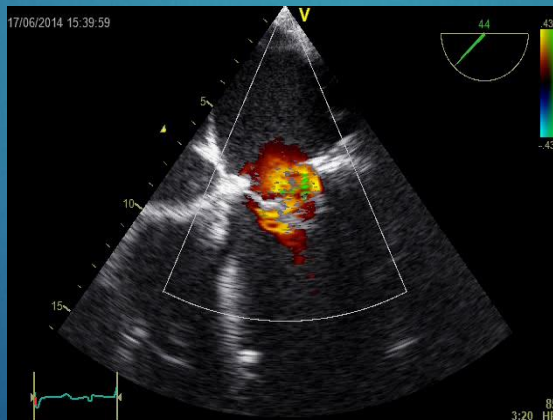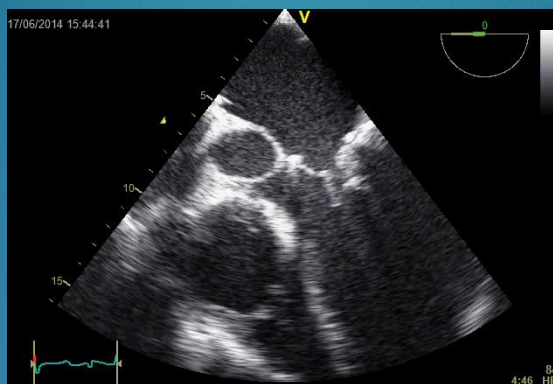


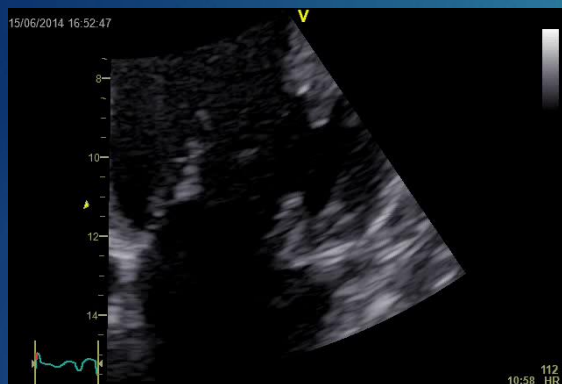MI-recidiv (CT -70) pre-perop

Preop
Chordaeruptur P2, AP58/IC47

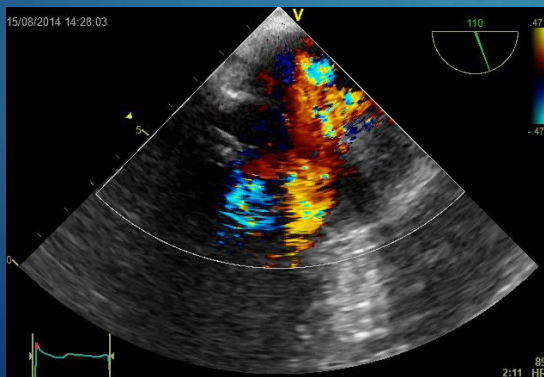
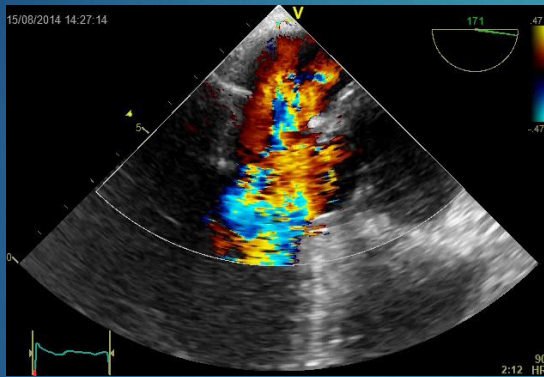
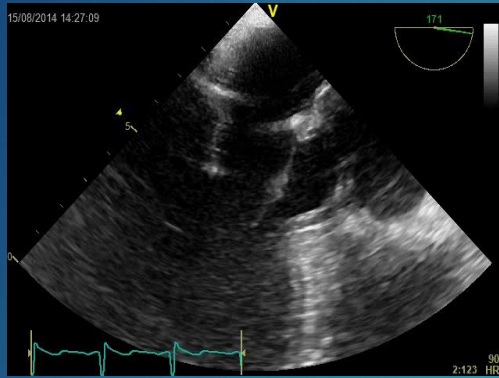
Op CE-ring 38mm, Neochordae
4 st
Perop: Inget läckage

Postop D5
Välfungerande plastik

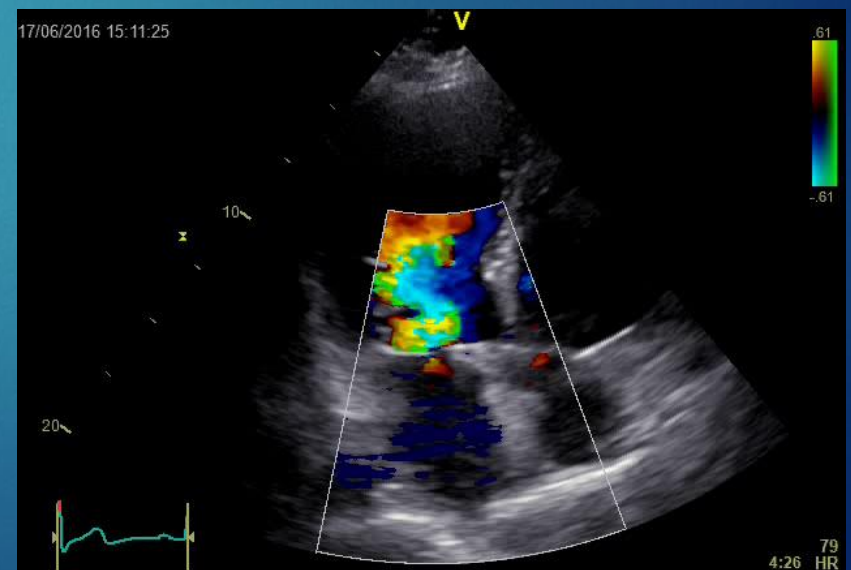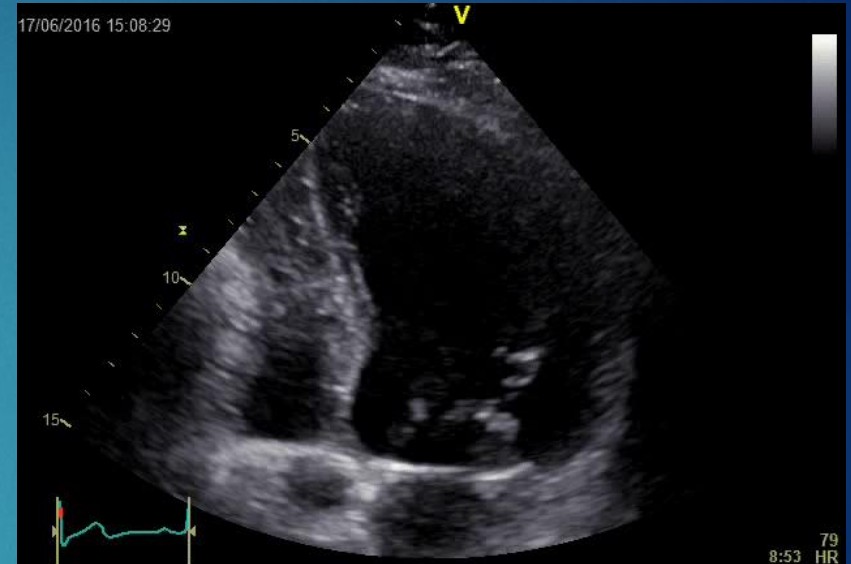


MI-recidiv (CT -70) postop

Postop 2 mån: VK 61mm, EF 44%,
måttlig MI '1,5', PL-prolaps
Mi-clip testas -> för hög gradient, tas
bort

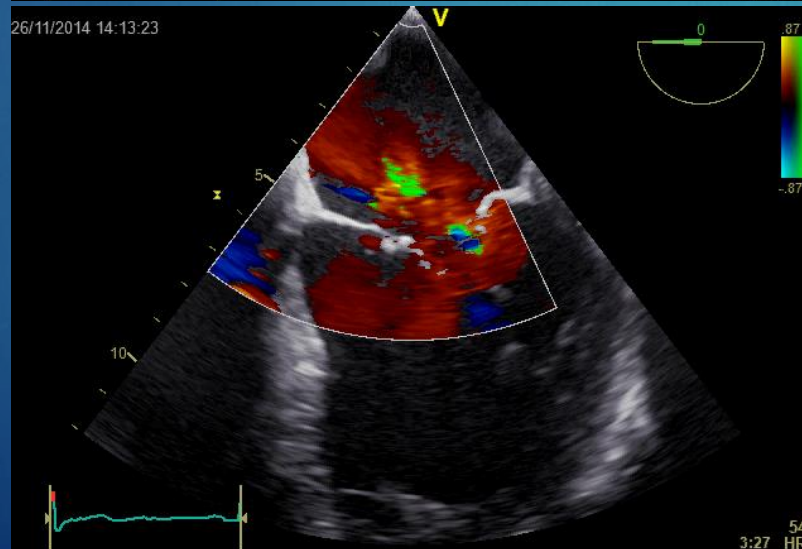
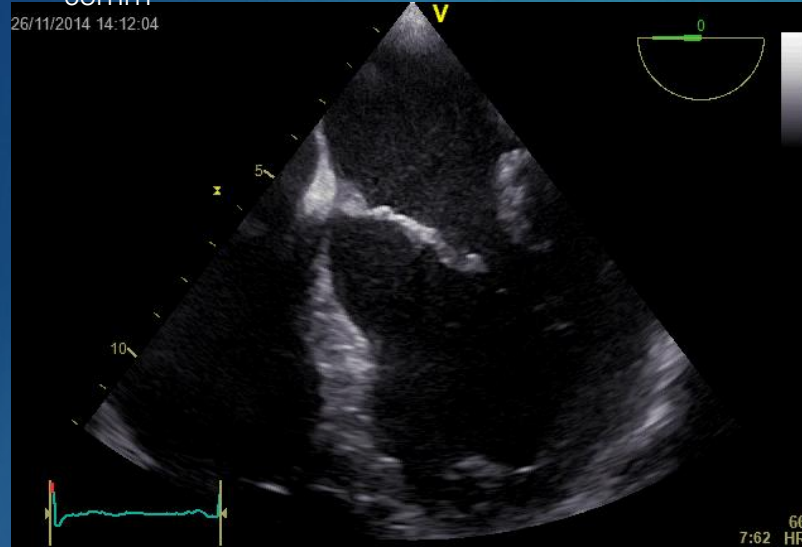


Postop 2 år
EF 64%, hyperdynamisk VK,
MI kvar men svårvärderad

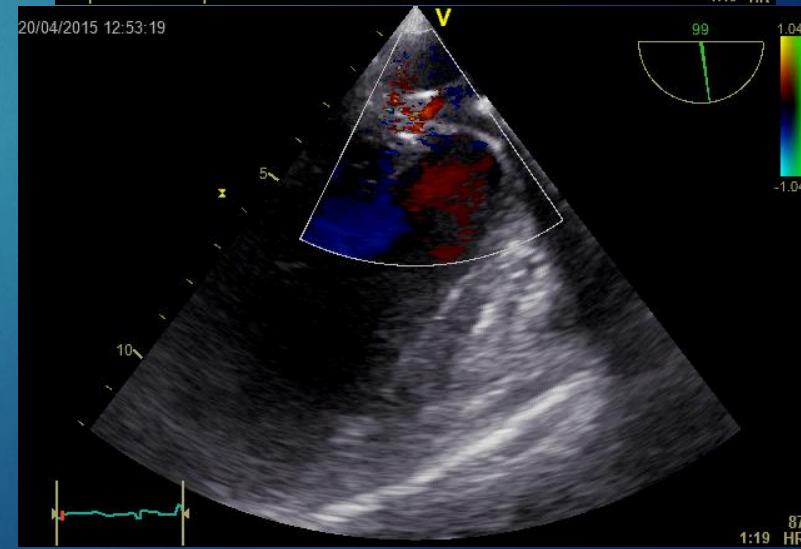
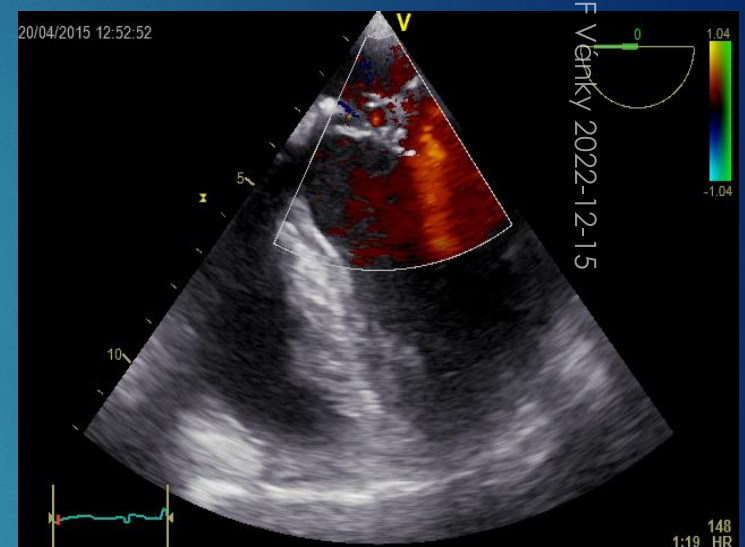


MI-recidiv (LJ -60) pre-perop

Preop
P2-prolaps, AP39/IC42, Dil VK
63mm

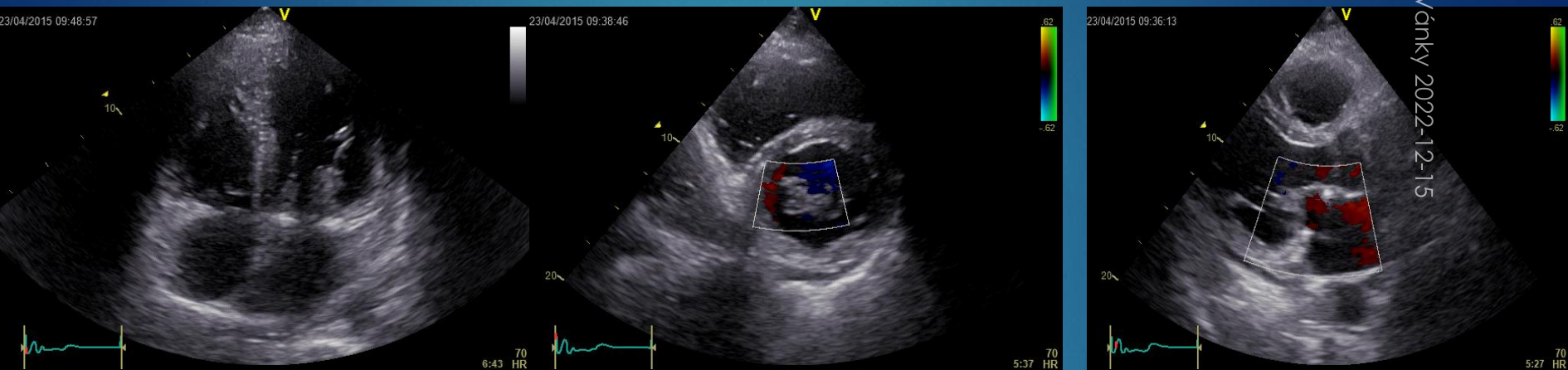


Op Phll-ring 36mm, Neochordae 2 st i P2
Perop: Liten splittrad MI, minskar med ökande tryck

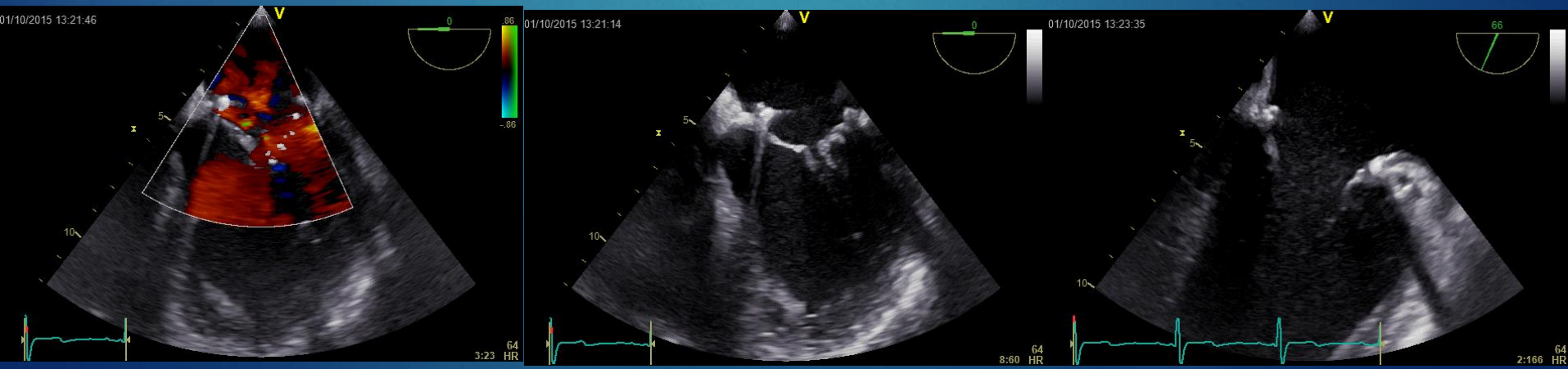


MI-recidiv (LJ -60) postop

Postop 2 mån: Lätt-måttl MI, lätt dil VK 62, God syst VK-funktion

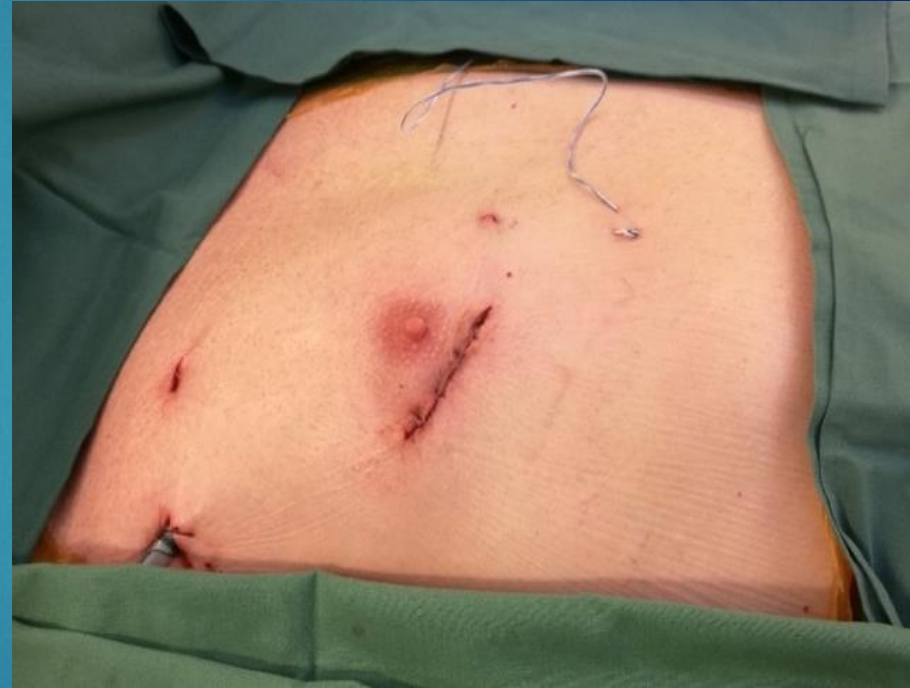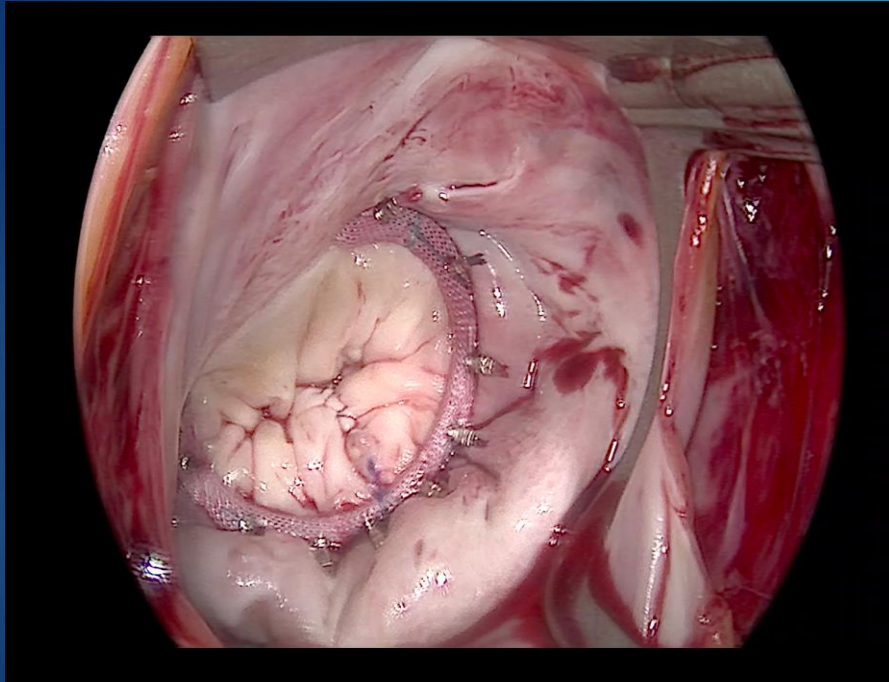


Postop 6 mån: Måttl MI, Normalstor VK med god syst funktion, P2-prolaps
Asymptomatisk, inga begränsningar -> aktiv expectans

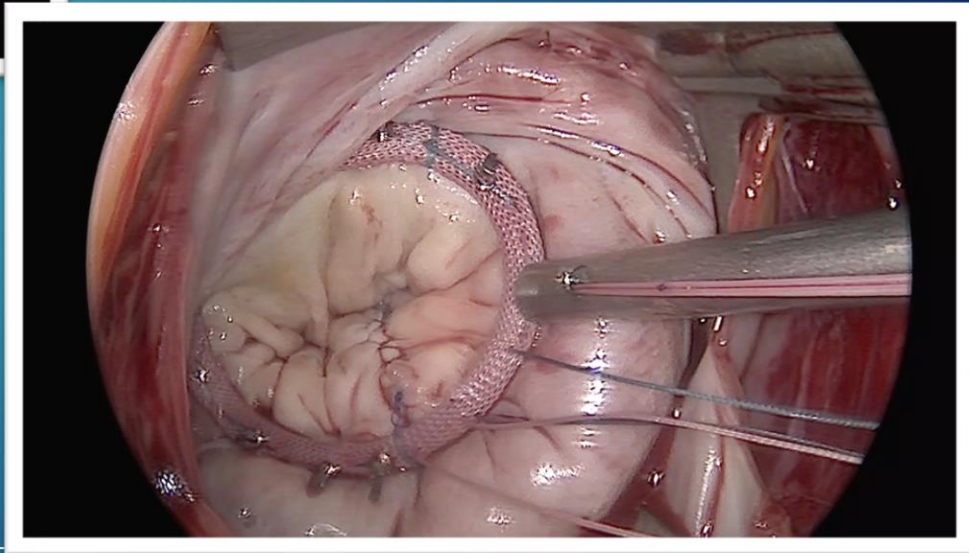
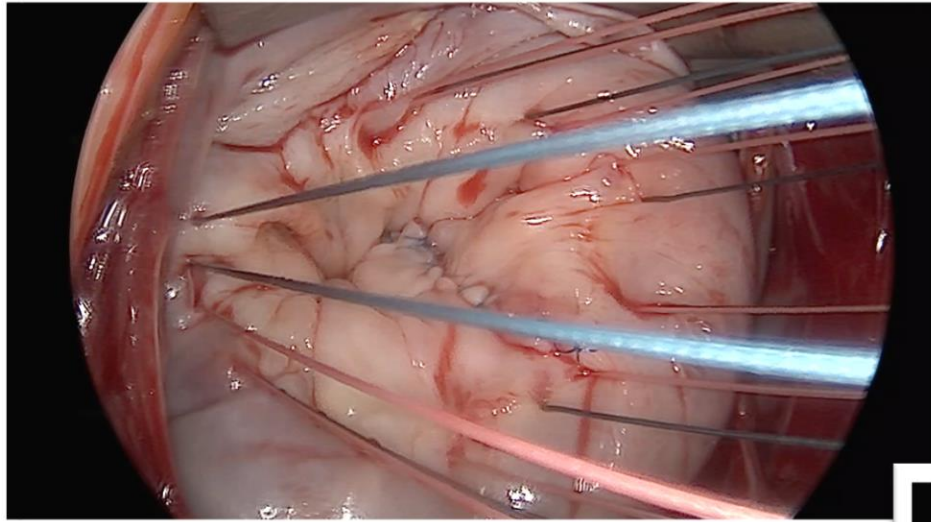


MIMS – Linköping 2019-2023

Farkas Vánky,



MIMS



Vår erfarenhet, N = 173

(2019-09-10 till 2023-11-01)

Mitralis (162)

- ▶ Redo 11 (7%)
- ▶ Cox maze IV 21 (13%)
- ▶ Tricuspid 18 (11%)
- ▶ Annat 15 (9%)

Övriga (11)

- ▶ Tumörer (myxom, fibroelastom) 4
- ▶ Tricuspidalisplastik/-protes 3
- ▶ PFO 2
- ▶ LV pseudoaneurysm redo 1
- ▶ Shunt Ao – RV redo 1

MIMS (162)

Diagnos - åtgärd

n	Insufficiens	Stenos	Endokardit	Plastik/protes-dysfunktion
Plastik	146 (96%)		1	→
Protes	6	1	1	8

Plastik N=147	Antal
Enbart ring	10
Resektion	113
Resektion + neochorda	9
Neochorda	7
Papillarmuskelplasti k	11
Baksegel	123
Framsegel	31

Resultat



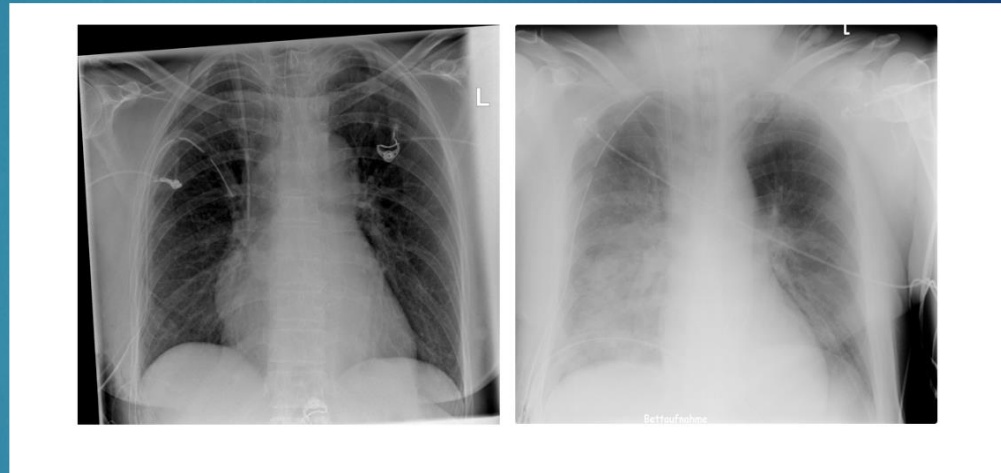
Preop - Op	Median, antal	Percentil 25:e-75:e
Ålder år	61	53-70
Kvinnor	21%	
EuroSCORE II	1.13	0.69-2.16
CCT min	98	83-115
ECC min	183	156-222
Optid min	238	196-280
Konvertering	6*	*5/70 första g

Postop	Median, antal	Percentil 25:e-75:e
CK-MB d1	30	22-52
Vårdtid postop (d)	5	4-7
Uppföljning		
Total mortalitet (50 mån, median 24 mån)	2 (1.2%)	D0, D29
MI > +1	0	
Reop klaffdysfunktion	0	

Unilateralt lungödem (UPE)

Upp till 20% efter MIMS

"In-hospital outcome with UPE after MIMVS was **not significantly worse** compared to non-UPE patients, and no differences were observed in the long-term follow-up. However, **prolonged aortic clamp time, worse renal and left ventricular function, pulmonary hypertension and transfusion are associated** with UPE."
(T Puehler, J. Clin. Med. 2021)



Sammanfattning MIMS

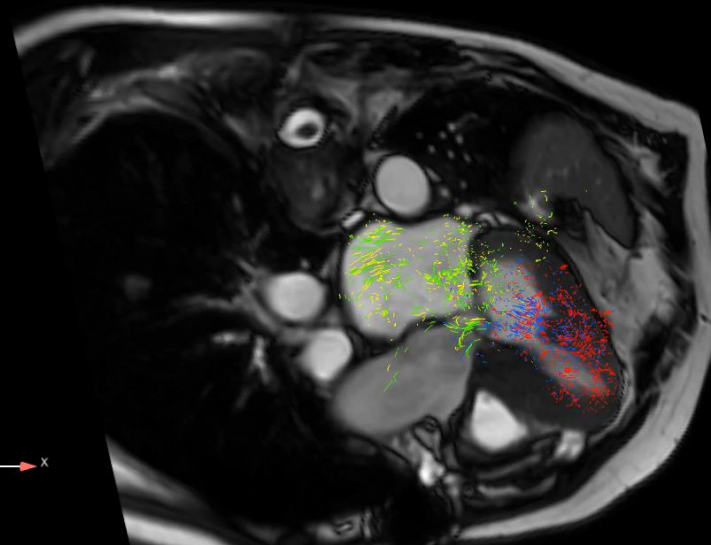
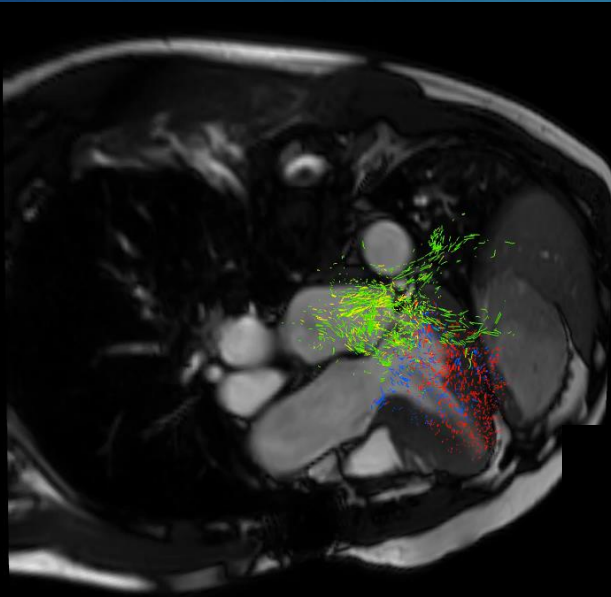
Patient

- Bättre visualisering
- Hög andel plastiker (96%)
- Kortare vårdtid (2d)
- Snabbare mobilisering
- Kortare sjukskrivning
- Alternativ till resternotomi vid redo
- Längre op tid (60-90 min)
- Specifika komplikationer att beakta

Organisation

- ▶ Lägsta volym
- ▶ Underlättar utbildning / delaktighet

4D-flowMRI





Tack för er
uppmärksamhet

Frågor?

